

# Porphyrias

Hervé Puy, Laurent Gouya, Jean-Charles Deybach

*Lancet* 2010; 375: 924–37  
Assistance Publique Hôpitaux de Paris, Centre Français des Porphyries, Hôpital Louis Mourier, Colombes, France (Prof H Puy MD, Prof L Gouya MD, Prof J-C Deybach MD); Institut National de la Santé et de la Recherche Médicale Unit 773, Centre de Recherches Biomédicales Bichat-Beaujon, Université Paris Diderot, Paris, France (Prof H Puy, Prof L Gouya, Prof J-C Deybach); and Université de Versailles, Saint Quentin en Yvelines, France (Prof L Gouya)

Correspondence to: Prof Jean-Charles Deybach, Centre Français des Porphyries, Hôpital Louis Mourier, 178 rue des Renouillers, 92701 Colombes CEDEX, France [jc.deybach@wanadoo.fr](mailto:jc.deybach@wanadoo.fr)

Hereditary porphyrias are a group of eight metabolic disorders of the haem biosynthesis pathway that are characterised by acute neurovisceral symptoms, skin lesions, or both. Every porphyria is caused by abnormal function of a separate enzymatic step, resulting in a specific accumulation of haem precursors. Seven porphyrias are the result of a partial enzyme deficiency, and a gain of function mechanism has been characterised in a new porphyria. Acute porphyrias present with acute attacks, typically consisting of severe abdominal pain, nausea, constipation, confusion, and seizure, and can be life-threatening. Cutaneous porphyrias present with either acute painful photosensitivity or skin fragility and blisters. Rare recessive porphyrias usually manifest in early childhood with either severe cutaneous photosensitivity and chronic haemolysis or chronic neurological symptoms with or without photosensitivity. Porphyrias are still underdiagnosed, but when they are suspected, and dependent on clinical presentation, simple first-line tests can be used to establish the diagnosis in all symptomatic patients. Diagnosis is essential to enable specific treatments to be started as soon as possible. Screening of families to identify presymptomatic carriers is crucial to decrease risk of overt disease of acute porphyrias through counselling about avoidance of potential precipitants.

## Introduction

Porphyrias are a group of eight panethnic inherited metabolic disorders of haem biosynthesis. Each results from a specific enzymatic alteration in the haem biosynthesis pathway (figure 1). Specific patterns of accumulation of the haem precursors 5-aminolaevulinic acid, porphobilinogen, and porphyrins are associated with characteristic clinical features—acute neurovisceral attacks, skin lesions, or both.<sup>1,2</sup> Eight enzymes bring about haem synthesis from glycine and succinyl CoA. The biosynthetic pathway begins in the mitochondria and, after three cytoplasmic stages, the final steps of haem formation take place in the mitochondria (figure 1).

Although haem is synthesised in every human cell for respiratory and oxidation-reduction reactions, it is mostly produced in the erythropoietic cells for haemoglobin synthesis and the liver parenchymal cells for synthesis of cytochromes and haemoproteins. Control of haem production differs between these two tissues, mostly because of differences in rates of synthesis of

5-aminolaevulinic acid. The first enzyme, 5-aminolaevulinic acid synthase (ALAS), is coded by two genes<sup>3</sup>—one erythroid specific (*ALAS2* on chromosome X) and one ubiquitous (*ALAS1* on chromosome 3). *ALAS1* is the rate-limiting enzyme in the production of haem in the liver and is controlled via negative-feedback regulation by the intracellular uncommitted haem pool<sup>4,5</sup> (figure 2).

In erythroid cells, synthesis of haem is regulated during erythroid differentiation in response to erythropoietin. In these cells, *ALAS2* synthesis is induced only during active haem synthesis. The rate is limited by iron availability and is not inhibited by haem.<sup>6</sup> Spleen and liver macrophages degrade haem and recycle iron after erythrophagocytosis through inducible haem oxygenase 1 (figure 2). Porphyrias are often classified as hepatic or erythropoietic according to the organ in which haem precursors accumulate (figure 1). However, a classification as acute porphyrias, cutaneous porphyrias, and rare recessive porphyrias based on clinical presentation is directly related to a simple biological diagnosis strategy and is more practical than are other classifications (figure 3).

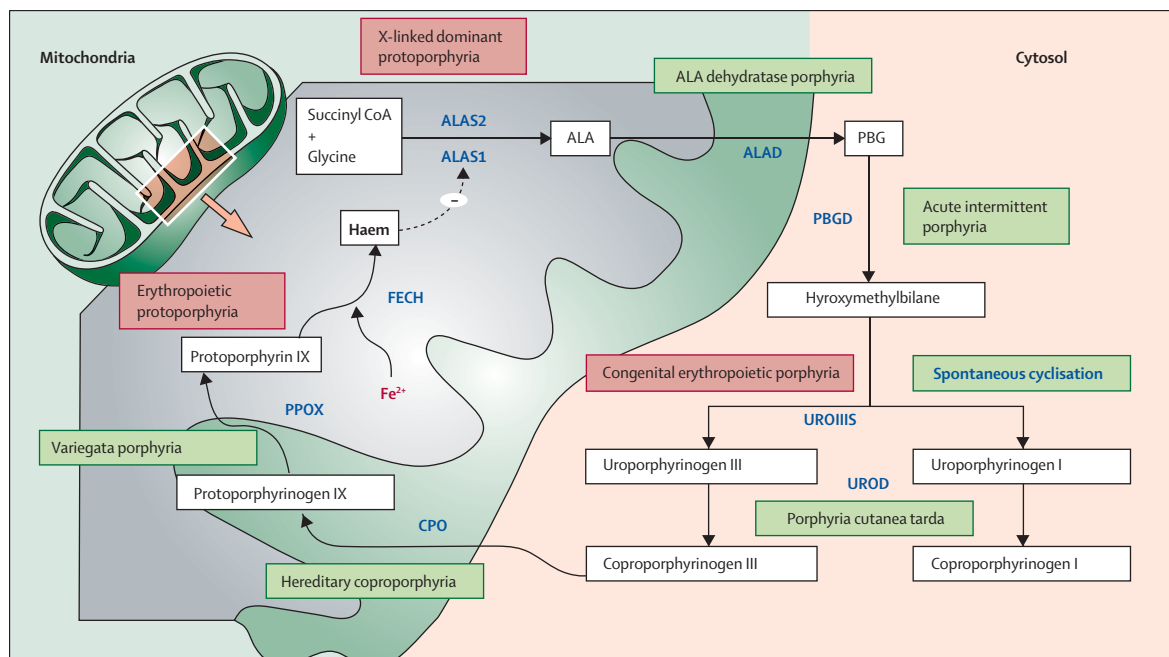
## Search strategy and selection criteria

We searched Embase, Medline, Ovid, and PubMed, with no restrictions on language or dates. We used the search terms “porphyria” and “genotype”, in combination with “phenotype”, “drugs”, “precipitating factors”, “pathogenesis”, “neuropathy”, “symptoms”, “pharmacogenetics”, “CYP450”, “gene therapy”, “mouse model”, “treatment”, “iron metabolism”, and “haem” plus “enzymes”. We largely selected publications from the past 5 years, but did not exclude commonly referenced and highly regarded older publications. We also searched the reference lists of articles identified by this search strategy and selected those we judged relevant. Review articles and book chapters are cited to provide readers with more details and references than this Seminar can give. Our reference list was modified on the basis of comments from peer reviewers.

## Acute porphyrias

### Presentation

People with autosomal-dominant acute porphyrias—acute intermittent porphyria, variegate porphyria, and hereditary coproporphyrin—can present with a sudden life-threatening crisis. These attacks are infrequent because penetrance is low and they are difficult to diagnose because they are non-specific. Acute attacks happen in all acute porphyrias. Skin lesions never develop in acute intermittent porphyria but are the only clinical manifestation in some patients with variegate porphyria (60% of patients), and rarely (5%) develop in patients with hereditary coproporphyrin (figure 4).<sup>1</sup> Acute intermittent porphyria is estimated to affect about one in 75 000 people in European countries, apart from in northern Sweden, where, because of a founder effect, it is more frequent (one in 1000).<sup>7,8</sup> Variegate porphyria might be half as



**Figure 1: Haem biosynthetic pathway and porphyrias**

Green boxes=hepatic porphyrias. Red boxes=erythropoietic porphyrias. ALA=5-aminolaevulinic acid. PBG=porphobilinogen. I, III, or IX=type isomers. ALAS=ALA-synthase. ALAD=ALA-dehydratase. PBGD=porphobilinogen deaminase. UROIII S=uroporphyrinogen III synthase. UROD=uroporphyrinogen decarboxylase. CPO=coproporphyrinogen oxidase. PPOX=protoporphyrinogen oxidase. FECH=ferrochelatase. Fe<sup>2+</sup>=ferrous iron.

prevalent as acute intermittent porphyria in most European countries and is especially common in South Africa because of a founder effect.<sup>9</sup> Acute attacks are very rare before puberty and after menopause, with a peak occurrence within the third decade. They are more common in women than in men.<sup>10,11</sup> Most patients have one or a few attacks and then recover fully for the rest of their lives. Less than 10% develop recurrent acute attacks.

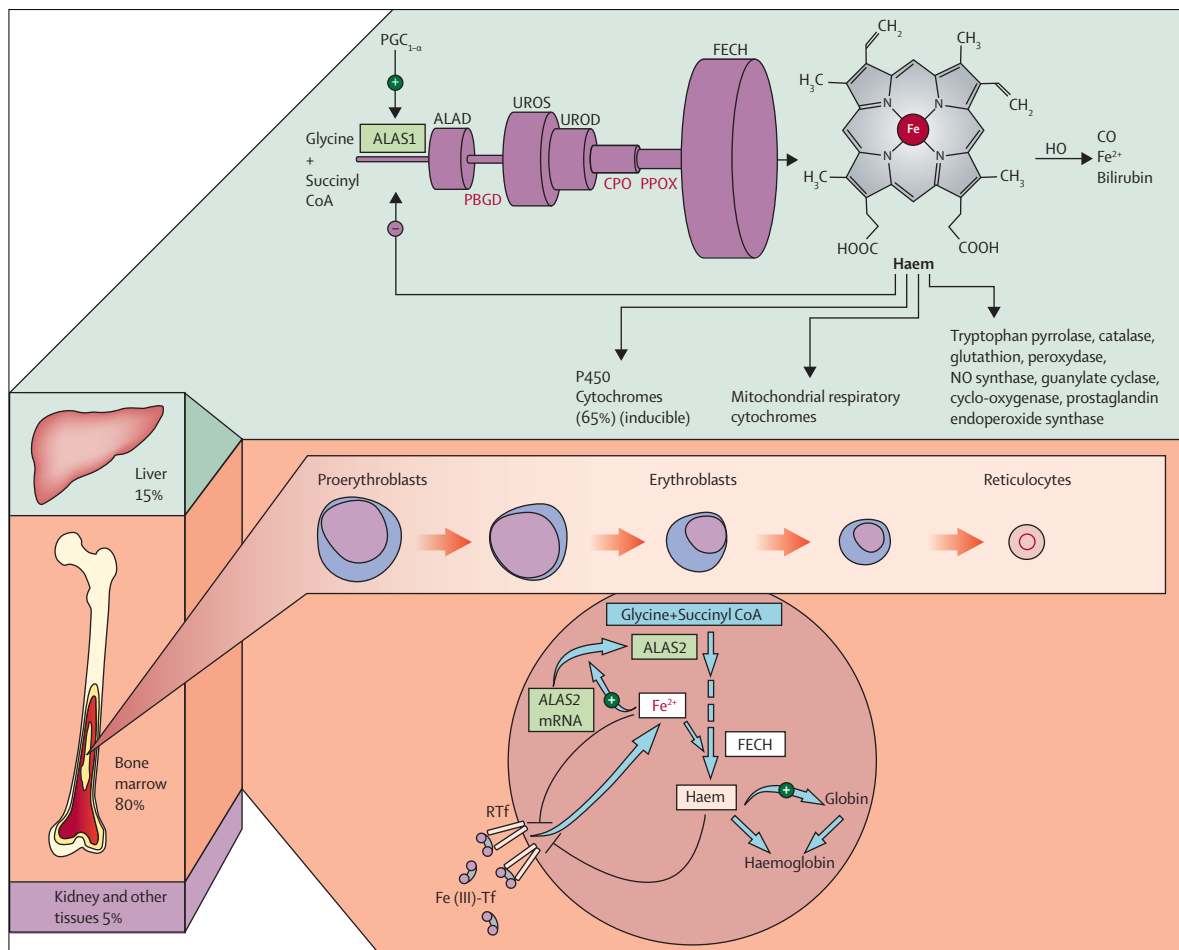
Porphyric attacks begin with a prodromic phase including minor behavioural changes such as anxiety, restlessness, and insomnia.<sup>12,13</sup> Most people with acute attacks present with severe abdominal pain, but this pain might also be felt in the back or thighs. Nausea, vomiting, and constipation are common. Tachycardia, excess sweating, and hypertension, which are symptoms of increased sympathetic activity, are often present.<sup>14</sup> Physical examination shows no abnormalities and X-ray analysis is normal or shows mild ileus of the bowel in most cases. During acute attacks, patients frequently become dehydrated and electrolyte imbalanced. Hyponatraemia attributable to inappropriate antidiuretic hormone secretion syndrome develops in 40% of cases, and when severe can lead to convulsions. Seizures in acute attacks can develop because of hyponatraemia or hypomagnesaemia or as a manifestation of porphyria. Occasionally, excretion of red or dark-coloured urine helps physicians with their investigations.

In 20–30% of patients, signs of mental disturbance such as anxiety, depression, disorientation, hallucinations, paranoia, or confusional states are reported. Most acute

attacks last for no longer than 1 or 2 weeks. When they last longer, gastrointestinal manifestations frequently lead to weight loss. Acute attacks can also be life threatening because of severe neurological complications. Neuropathy often develops when drugs that are known to be porphyrinogenic are used during an attack. Neuropathy is mostly motor—in the early stages, pain in the arms and legs is very common (muscle pain), and weakness generally begins in the proximal muscles, more frequently in the arms than in the legs. Limb paresthesia, when it occurs, can be very local. Muscle weakness can progress and lead to tetraplegia, with respiratory and bulbar paralysis and death. Recovery from paralysis is gradual and in some cases incomplete, with sequelae mostly in the arms and legs. Pyramidal signs, cerebellar syndrome, transitory blindness, or consciousness abnormalities (from somnolence to coma) can arise. Cerebrospinal fluid is normal in most cases. Porphyric neuropathy is far less common than it was in the past, and acute attacks are rarely fatal. Clinical manifestations are non-specific in most cases. Biochemical analysis is necessary for diagnosis of an acute attack and to define the type of porphyria.

#### Diagnosis

Examination of urine for excess porphobilinogen is the essential first-line test for patients with a suspected attack of acute porphyria (figure 3).<sup>15–17</sup> Measurement of 5-aminolaevulinic acid is not essential to establish the diagnosis but can be helpful for differentiation of the



**Figure 2: Regulation of haem biosynthesis in the liver and in the bone marrow**

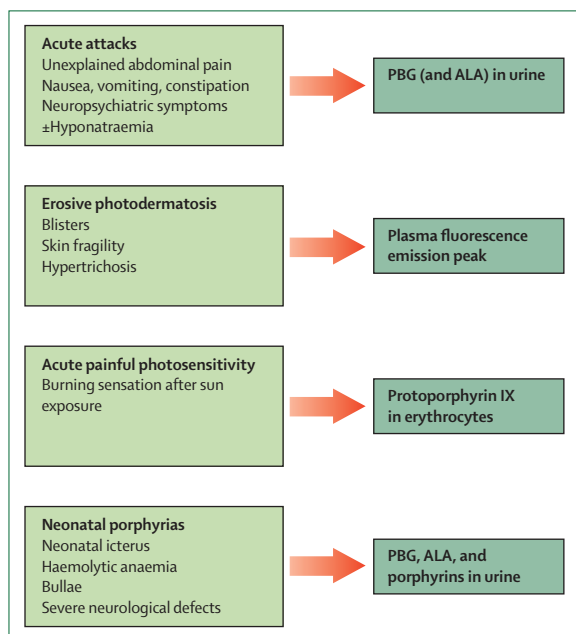
PGC<sub>1-α</sub>=peroxisome proliferator-activated receptor-γ coactivator 1α. ALA=5-aminolaevulinic acid. ALAS1=ALA-synthase. ALAD=ALA-dehydratase. PBGD= porphobilinogen deaminase. UROS=uroporphyrinogen synthase. UROD=uroporphyrinogen decarboxylase. CPO=coproporphyrinogen oxidase. PPOX=protoporphyrinogen oxidase. FECH=mitochondrial ferrochelatase. NO=nitric oxide. HO=haem oxygenase. CO=carbon monoxide. Fe<sup>2+</sup>=ferrous iron. Tf=transferrin. rTf=transferrin receptor. mRNA=messenger RNA.

disorder from other metabolic causes of abdominal pain, eg, lead poisoning or the rare 5-aminolaevulinic acid dehydratase porphyria. Urinary porphobilinogen and 5-aminolaevulinic acid are increased in all three acute hepatic porphyrias (acute intermittent porphyria, hereditary coproporphyria, and variegate porphyria) although the concentrations are higher and longer lasting in acute intermittent porphyria than in the other two types (hereditary coproporphyria and variegate porphyria). Measurement of urinary porphyrins is unhelpful and might be misleading because of frequent and non-specific coproporphyrinuria in many common disorders. With a recorded porphobilinogen overexcretion (>10 times the upper limit), treatment can be started immediately, with further laboratory investigations used to define the porphyria type in the proband (table 1).

For diagnosis of the type of acute porphyria in the proband, plasma fluorescence emission spectroscopy is a first-line test because a peak at 624–628 nm establishes the diagnosis of variegate porphyria.<sup>18,19</sup> However, it does not

distinguish acute intermittent porphyria from hereditary coproporphyria, for which the emission peak at 620 nm is usually present for both types.<sup>20</sup> Urinary porphyrin analysis alone is not sufficient for discrimination (table 1). Total faecal porphyrin concentration is increased in variegate porphyria, with protoporphyrin concentrations (protoporphyrin IX) greater than those for coproporphyrin, whereas it is usually normal in acute intermittent porphyria. Total faecal porphyrin concentration is raised in hereditary coproporphyria, with coproporphyrin as the main component and a ratio of isomer III to isomer I greater than 2·0 (table 1). When present, a 50% decrease of porphobilinogen-deaminase activity can positively identify acute intermittent porphyria patients.

During remission, urine, faecal, and plasma porphyrin concentrations are generally normal in all three acute porphyrias.<sup>17</sup> The most sensitive metabolite test for variegate porphyria that is in remission or presymptomatic is fluorescence emission spectroscopy of plasma (if patient is older than 15 years, with a 60% sensitivity and 100%

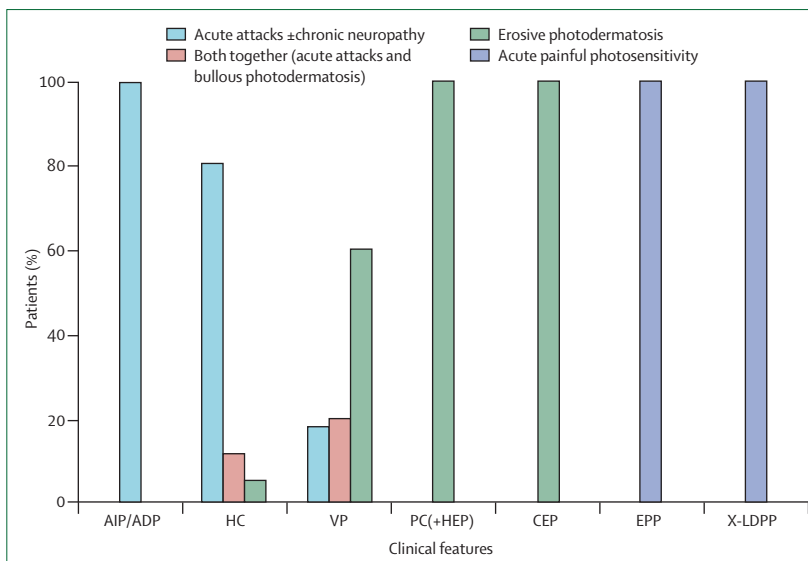


**Figure 3: First-line tests for diagnosis of porphyrias**  
PBG=porphobilinogen. ALA=5-aminolaevulinic acid.

specificity). For hereditary coproporphyria, a ratio of faecal coproporphyrin isomer III to isomer I of more than 2.0 is sensitive in adults but the sensitivity of this ratio is not established in children.<sup>20-22</sup> Family screening is essential to prevent acute attacks in those with latent disease. DNA analysis to identify the mutation is the gold standard.<sup>23-26</sup> For DNA analysis, previous identification of the mutation in an unequivocally affected family member is needed. Genes for all porphyrias have been characterised, and large numbers of disease-specific mutations have been identified. Regularly updated lists of mutations are available from the Human Gene Mutation Database. Enzyme measurements are reserved for families in which a mutation cannot be identified (table 1). However, measurement of protoporphyrinogen, coproporphyrinogen oxidases, and even the widely used porphobilinogen-deaminase assay should be undertaken in a porphyria reference centre.<sup>27,28</sup>

### Pathogenesis and treatment

All clinical features of an acute attack can be explained by lesions of the nervous system. The leading hypothesis is that 5-aminolaevulinic acid or other metabolites that are overproduced by the liver are neurotoxic,<sup>29,30</sup> and this notion is consistent with the substantial benefit of liver transplantation in patients with severe acute intermittent porphyria.<sup>31</sup> Acute attacks are precipitated by events that either directly induce ALAS1<sup>32</sup> or increase the demand for haem synthesis in the liver and subsequently de/inhibit ALAS1 (figure 2).<sup>29</sup> These events include hormonal fluctuations during the menstrual cycle, fasting, smoking,<sup>33</sup> infections, and exposure to porphyrinogenic drugs. Most drugs that exacerbate porphyria are closely associated with



**Figure 4: Clinical features of porphyrias**

AIP=acute intermittent porphyria. ADP=5-aminolaevulinic acid (ALA) dehydratase porphyria. HC=hereditary coproporphyria. VP=variegate porphyria. PCT=familial and sporadic porphyria cutanea tarda. HEP=hepatoerythropoietic porphyria. CEP=congenital erythropoietic porphyria. EPP=erythropoietic protoporphyria. X-LDPP=X-linked dominant erythropoietic protoporphyria.

induction of cytochrome P450 enzymes, which increase hepatic haem turnover. Inflammatory and infectious diseases induce hepatic expression of the acute-phase protein haem oxygenase 1, which catabolises haem. Transcription of ALAS1 seems to be upregulated by the transcriptional factors peroxisome proliferator-activated receptor  $\gamma$  coactivator 1 $\alpha$  (PGC-1 $\alpha$ )<sup>34</sup> and peroxisome proliferator-activated receptor  $\alpha$  (PPAR $\alpha$ ).<sup>35</sup> This finding could explain why acute intermittent porphyria is associated with impaired liver energy metabolism and chronic undernutrition.<sup>36</sup>

Treatment (table 2) should be started promptly and any precipitating factors—especially drugs (including oestrogens and progestagens)—avoided, underlying infection should be treated and hypocaloric diets corrected.<sup>37</sup> Complete lists of potentially safe and unsafe drugs are available on the internet (for the USA, and the European Union countries, South Africa, and Canada).

Patients often need high doses of opiates in combination with an antiemetic and a phenothiazine, such as chlorpromazine for anxiety and restlessness and to decrease need for analgesics. Careful management of fluid balance, with avoidance of large volumes of hypotonic dextrose, is necessary to limit the risk of severe hyponatraemia, which could provoke convulsions. An adequate intake of calories should be ensured, given orally as carbohydrate-rich food supplements (more than half of energy intake), or infused as normal saline with 5% dextrose when the patient has severe vomiting. Cardiovascular complications such as hypertension and tachycardia are rarely severe, therapy with  $\beta$  blockers is needed in some cases.

For the Human Gene Mutation database see <http://www.hgmd.org>

For lists of drugs that are safe and unsafe during acute porphyria attacks in European Union countries, South Africa, and Canada see <http://www.drugs-porphyrin.org>

For lists of drugs that are safe and unsafe during acute porphyria attacks in USA see <http://www.porphyrin.foundation.com>

|  | Main clinical presentation                         | Biochemical findings in symptomatic patients* |   |                            |                   | Methods to detect presymptomatic carriers   |
|--|--|---|---|----------------------------|-------------------|---|
|  |  | Urine   | Stool   | Red blood cells (RBC)      | Plasma peak† (nm) |   |
| <b>Acute porphyria</b>                         |  |   |   |                            |                   |   |
| Acute intermittent porphyria (176 000)         | Acute attacks                                      | PBG, ALA, porphyrins                          | Only useful to distinguish AIP from HC and VP | ..                         | 618–620           | PBGD gene sequencing, low PBGD activity in RBC (classic form) or in lymphoblastoid cells (variant form) |
| <b>Acute or cutaneous porphyrias</b>           |  |   |   |                            |                   |   |
| Hereditary coproporphyrin (121 300)            | Acute attacks or skin fragility and blisters       | PBG, ALA, porphyrins                          | Copro III, ratio isomer III/I>2-0             | ..                         | 618–620           | CPOX gene sequencing, low CPOX activity in lymphocytes  |
| Variegate porphyria (176 200)                  | Acute attacks or skin fragility and blisters       | PBG, ALA, copro III                           | Proto IX >copro III                           | ..                         | 624–627           | Plasma peak only in adults PPOX gene sequencing, low PPOX activity in lymphocytes                       |
| <b>Cutaneous porphyrias</b>                    |  |   |   |                            |                   |   |
| Sporadic porphyria cutanea tarda (176 090)     | Skin fragility and blisters                        | Uro I/III, hepta                              | Isocopro, hepta                               | ..                         | 618–620           | Not defined   |
| Familial porphyria cutanea tarda (176 100)     | Skin fragility and blisters                        | Uro I/III, hepta                              | Isocopro, hepta                               | ..                         | 618–620           | UROD gene sequencing, low UROD activity in RBC  |
| <b>Painful photosensitive porphyrias</b>       |  |   |   |                            |                   |   |
| Erythropoietic protoporphyria (177 000)        | Burning sensation after sun exposure               | Normal  | With or without proto IX                      | Free-proto IX (>80%)       | 630–634           | FECH gene sequencing including detection of weak IVS3-48C allele, low FECH activity in lymphocytes      |
| X-linked dominant protoporphyria (300 752)     | Burning sensation after sun exposure               | Normal  | Proto IX                                      | Free and Zn-proto IX (40%) | 630–634           | ALAS2 gene sequencing   |
| <b>Rare recessive porphyrias</b>               |  |   |   |                            |                   |   |
| ALA dehydratase porphyria (125 270)            | Acute and chronic neuropathy                       | ALA, copro III                                | Normal  | +/- Zn-proto IX            | ..                | ALAD gene sequencing, low ALAD activity in RBC  |
| Congenital erythropoietic porphyria (606 938)* | Severe photosensitivity with or without haemolysis | Uro I, copro I                                | Copro I                                       | Uro I, copro I             | 615–618           | URO5 and GATA1‡ genes sequencing, low UROS activity in RBC  |
| Hepatoerythropoietic porphyria (176 100)       | Severe photosensitivity                            | Uro III, hepta                                | Isocopro, hepta                               | +/- Zn-proto IX            | 618–620           | UROD gene sequencing, low UROD activity in RBC  |

Investigations should be done in association with specialist porphyria centres. ALA=5-aminolaevulinic acid. PBG=porphobilinogen. AIP=acute intermittent porphyria. VP=variegate porphyria. HC=hereditary coproporphyrin. Uro=uroporphyrin. Copro=coproporphyrin. Proto=protoporphyrin. Isocopro=isocoproporphyrin. Hepta=heptacarboxyl-porphyrin. I or III=type isomers. Zn=zinc. OMIM=Online Mendelian Inheritance in Man. \*DNA analysis should be used whenever possible to confirm diagnosis in proband. Identification of mutation in unequivocally affected family member is a prerequisite for family investigation. †Fluorescence emission peak in nm. ‡X-linked erythroid-specific transcription factor GATA-binding protein 1 mutation has been reported in one case of congenital erythropoietic porphyria.

**Table 1: Diagnosis of porphyria type (OMIM) in a proband and strategies for family investigations**

Very occasionally, acute attacks are accompanied by a severe adrenergic crisis with dangerous hypertension, encephalopathy, seizures, and ischaemic changes on a CT brain scan. Posterior reversible encephalopathy syndrome has been shown on MRI during acute attacks with severe encephalopathy. Intravenous infusion of magnesium sulphate can be effective for control of adrenergic symptoms. Onset of a motor neuropathy is often characterised by severe pain and stiffness in the thighs and back, and then loss of tendon reflexes and motor paralysis. When vital capacity becomes severely reduced by paralysis of the intercostal muscles, artificial ventilation is necessary.

Intravenous haemin administration, which inhibits upregulated ALAS1 and curtails urinary excretion of 5-aminolaevulinic acid and porphobilinogen, is the specific (or aetiopathogenic) treatment of choice.<sup>38,39</sup> Most patients with uncomplicated attacks improve within 5 days.<sup>12</sup> However, human haemin will not reverse

an established neuropathy, but might prevent neuropathy onset and halt further progression if given sufficiently early. A stable preparation of human haemin solution stabilised with arginine (Normosang)<sup>40</sup> is widely available, whereas in the USA a form of lyophilised haemin (Panhaematin)<sup>41</sup> is available. Measurement of urinary porphobilinogen excretion is useful to document the metabolic response to human haemin. Few side-effects have been reported for short-term use of human haemin stabilised with arginine. Coagulopathies reported with other haem preparations do not develop with stabilised haemin with arginine.<sup>12</sup> Administration after 1:1 dilution in 4–20% human serum albumin increases haem solubility and stability and lowers the risk of vein injury.<sup>38,42</sup> Attacks during pregnancy have been treated without any apparent adverse effects to either mother or child.<sup>43,44</sup>

Less than 10% of patients have recurrent acute attacks without clearly identified precipitating factors. Advice

about management of these attacks should be sought from a reference porphyria centre. Management of repeated attacks that are severe enough to need admission is difficult, and long-term treatment with human haemin is needed. Regular treatment with a once-per-week single dose can help to control the disease. The most frequently reported event after several courses of haem therapy is the disappearance of the superficial venous system. Most of these patients will probably need permanent indwelling venous catheters, which have many attendant complications. A single dose of human haemin contains 22.7 mg of iron. Therefore, iron overload is possible in patients who are given regular doses. A few patients with severe acute intermittent porphyria have received liver transplants. This intervention returns 5-aminolaevulinic acid and porphobilinogen excretion to normal, abolishes acute attacks, and improves quality of life. Thus, liver transplantation should be considered for selected patients with the most severe form of acute intermittent porphyria.<sup>45</sup>

Carriers of the gene defect, symptomatic or not, should be counselled about maintenance of a healthy diet with regular meals, avoidance of alcohol<sup>46</sup> and smoking, and use of the list of potentially safe and unsafe drugs.<sup>47</sup> When drugs are prescribed for porphyria, benefit versus risk should always be considered in conjunction with the severity of the underlying disorder that needs treatment and the disease activity of the porphyria. When difficult decisions about treatment have to be made, a national porphyria reference centre should be contacted. Early and accurate diagnosis combined with efficient counselling and treatment has greatly reduced fatality rates in acute porphyrias. Finally, patients with both symptomatic and latent disease have increased risks of hypertension,<sup>10,48</sup> hepatocellular carcinoma,<sup>10,49–52</sup> and chronic renal failure,<sup>53</sup> and these risks need to be discussed individually with the patients.

## Cutaneous porphyrias

### Bullous porphyrias

Variete porphyria, hereditary coproporphyria, and porphyria cutanea tarda share the same chronic cutaneous photosensitivity. Porphyria cutanea tarda is the most frequent type of porphyria worldwide and presents with skin symptoms only. Variete porphyria and hereditary coproporphyria can present with either cutaneous or neuropsychiatric symptoms (figure 4). Laboratory diagnosis is essential to avoid misclassification and unexpected acute attacks (figure 3 and table 1). Lesions are restricted to sun-exposed areas such as the backs of the hands, face and neck; some women might also develop lesions on the legs and feet (figure 5).<sup>54</sup> Skin fragility is perhaps the most specific feature, in which negligible trauma is followed by superficial erosion that is soon covered by a crust. Secondary infection is common. Bullae, blisters, or

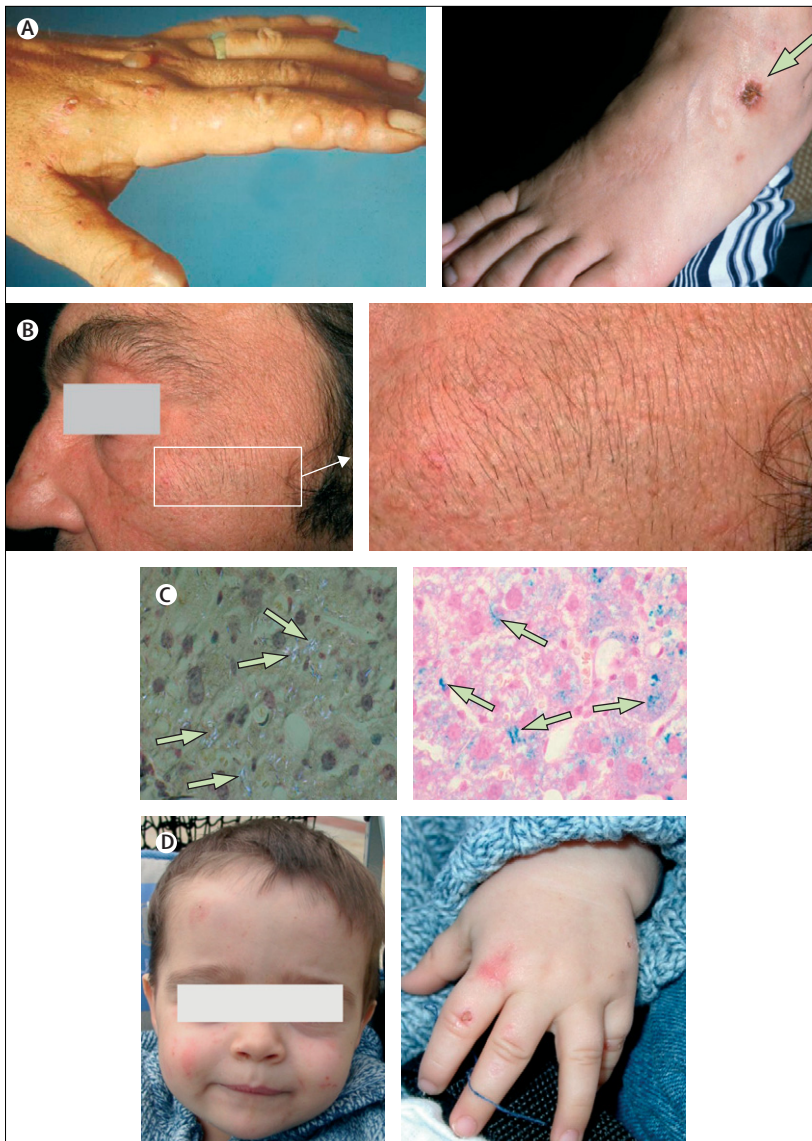
|   | Treatment measures   |
|---|--|
| Preventive  | Prescribe drugs from safe drug list; avoid alcohol, smoking, and soft drugs (cannabis), dieting, and fasting; carry medical alert cards or jewellery   |
| Supportive  | Stop porphyrinogenic drugs   |
| Specific  |  |
| Repress haem synthesis                            | Haemin* (4 mg/kg per day for 3–4 consecutive days)   |
| Hyponatraemia and fasting                         | Maintain fluid and calorie intake<br>Mild cases: 2 L normal saline containing 5–10% dextrose or glucose (>200 g per day)<br>Severe hyponatraemia: infusion of 3% saline (500 mmol/L) correction <12 mmol/L per day |
| Treatment of symptoms                             |  |
| Autonomic neuropathy                              |  |
| Abdominal pain                                    | Opiates (pethidine, morphine, and diamorphine); aspirin, paracetamol, and dihydrocodeine   |
| Vomiting and sedation                             | Promazine, chlorpromazine, cyclizine, and ondansetron  |
| Constipation                                      | Bulk laxatives, senna, and lactulose   |
| Hypertension and tachycardia                      | β blockers (propranolol, atenolol, and labetalol)  |
| Abnormal sphincter function                       | Urethral catheter  |
| Arrhythmia  | β blockers, follow up patient in intensive care unit   |
| Peripheral sensory or motor neuropathy            |  |
| Limb pain, back pain, or both                     | Opiates  |
| Muscle weakness                                   | Early activating physiotherapy   |
| Respiratory muscle paresis                        | Follow up patient in intensive care unit; mechanical ventilator  |
| Bulbar paresis (dysarthria, dysphagia, dysphonia) | Sign of poor prognosis, nasogastric tube, and speech therapy   |
| CNS involvement                                   |  |
| Insomnia and anxiety                              | Lorazepam  |
| Hallucinations                                    | Chlorpromazine   |
| Consciousness impairment                          | Follow up patient in an intensive care unit  |
| Convulsions                                       | Follow up patient in an intensive care unit; monitor and correct hyponatraemia; diazepam (IV 10 mg once only), clonazepam, magnesium sulphate, gabapentin or clonazepam if prolonged treatment is needed           |
| Extremely severe recurrent cases                  | Poor quality of life; consider liver transplantation   |

IV=intravenous. CNS=central nervous system. \*Human haemin stabilised with arginine (Normosang) is available worldwide, apart from in the USA where lyophilised haemin is available.

Table 2: Management of acute porphyrias

vesicles take several weeks to heal. White papules (milia) can develop in areas of bullae, especially on the backs of hands. Previous areas of blisters appear atrophic or brownish. Hypertrichosis is common on the upper cheeks, ears, and arms (figure 5). Increased pigmentation of sun-exposed areas is common. Skin symptoms show seasonal variations, with greater intensity in the summer and autumn than in other seasons. Rare ocular complications have been reported in porphyria cutanea tarda, such as ocular pain and photophobia.<sup>55</sup> Variable degrees of liver dysfunction are frequent in patients with this disorder, especially in association with excessive alcoholic intake. However, in patients with alcoholic cirrhosis, porphyria cutanea tarda is very rare, suggesting an underlying constitutional abnormality that might predispose the liver to development of the disease.

For consensus-agreed common prescribing difficulties in anaesthesia, anticonvulsants, and hormonal contraception see <http://www.porphyrria-europe.org>



**Figure 5: Signs and clinical symptoms of cutaneous hepatic and hepatoerythropoietic porphyrias**

Cutaneous symptoms in variegate porphyria, hereditary coproporphyrin, and porphyria cutanea tarda; blisters (arrow heads) and bullae (arrow; A); hypertrichosis (B); uroporphyrin needles (arrows) and iron overload (Perl's staining) in liver biopsy samples of patients with porphyria cutanea tarda (C); and clinical presentation of hepatoerythropoietic porphyria (D).

In bullous porphyrias, large amounts of porphyrins accumulate in the skin. The tetrapyrrolic nucleus of porphyrins renders them highly photoreactive and they absorb radiation energy in the visible range of about 400 nm. Once excited to a singlet state, porphyrin molecules might return to their ground state by a transfer of energy to various biological molecules that promotes peroxidation of membrane lipids and oxidation of nucleic acids and polypeptides.<sup>56</sup> Histological examination of skin reveals cell-poor blisters beneath the epidermis, the multilayering of the basement membranes, and deposition of hyaline material, in and surrounding dermal blood vessels. These protein deposits stain

positively with periodic acid Schiff reagent. Results of immunochemical studies<sup>57–59</sup> show immunoglobulin, fibrinogen, and complement in the vicinity of vessel walls. Altogether, these findings suggest that the principal site of photo injury is the blood vessels of the papillary dermis. A skin biopsy sample is useless and even contraindicated for both positive and causal diagnoses that are easily achieved with biochemical tests.

Plasma fluorescent spectrum is the best initial test for diagnosis of cutaneous porphyrias,<sup>60</sup> differentiating between variegate porphyria<sup>19</sup> and porphyria cutanea tarda (figure 3 and table 1). Excretion profiles of urinary and faecal porphyrins are also useful diagnostic measures (table 1). In patients with symptomatic porphyria cutanea tarda, the typical porphyrin excreted in the faeces, other than a large excretion of uroporphyrin and 7-carboxy-porphyrin, is isocoporphyrin.<sup>61,62</sup> However, excretion profiles become normal after long-term remission. Porphyria cutanea tarda is caused by a deficiency of uroporphyrinogen decarboxylase activity—at least in the liver.<sup>63</sup> It is a heterogeneous disease.

The sporadic subtype (75% of cases) is most often identified in male patients without a family history of the disease. In this disorder, uroporphyrinogen decarboxylase activity is deficient only in the liver during overt disease.<sup>64</sup> Sporadic porphyria cutanea tarda is a complex disease in which both a multigenic predisposition and environmental risk factors are needed for symptoms to develop. The familial subtype (25% of cases) has an earlier onset than does the sporadic subtype, and arises equally in both sexes. It is transmitted as an autosomal-dominant mendelian disorder of low penetrance, attributable to a family-specific *UROD* gene defect that leads to a constitutive 50% uroporphyrinogen decarboxylase deficiency. The ability to differentiate between the sporadic and familial subtypes is useful in genetic counselling to detect presymptomatic familial subtype patients and prevent their exposure to precipitating factors. However, benefits of identification of patients with familial subtypes are still controversial and need to be assessed. Activity of erythrocyte uroporphyrinogen decarboxylase is normal in the sporadic subtype and reduced in the familial subtype, in which mutation screening is useful to detect symptom-free relatives (table 1).<sup>65,66</sup>

The same risk factors contribute to either a partial inactivation of hepatic uroporphyrinogen decarboxylase in sporadic porphyria cutanea tarda or severe inactivation in the familial subtype.<sup>67</sup> Porphyria cutanea tarda seems to be a disease in which symptoms develop when residual, hepatic uroporphyrinogen decarboxylase decrease below a threshold of about 25%. The risk factors that contribute to inactivation or inhibition of this enzyme are mainly alcohol abuse, oestrogens, hepatitis C, and to a lesser extent HIV infections and genetic haemochromatosis.<sup>67–72</sup> These precipitating factors act either alone or in combination with hepatic iron overload, an almost universal finding in porphyria cutanea tarda, to generate

an iron-dependent oxidative mechanism. Results of a meta-analysis<sup>73</sup> show that *HFE C282Y* and *H63D* alleles in different genotypic combinations are associated with a three to 48 times greater risk of porphyria cutanea tarda than is the wild type genotype. Liver biopsy samples frequently show siderosis (figure 5). Transferrin saturation and serum iron and ferritin concentrations are frequently increased.<sup>74,75</sup> Additionally, polymorphisms in *TFRC1* and *CYP1A2* genes<sup>76</sup> confer a heightened risk of porphyria cutanea tarda.

Hepatic siderosis in porphyria cutanea tarda results in part from deregulated hepcidin (*HAMP*) expression, independent of the *HFE* genotype.<sup>77</sup> Hepatic uroporphyrinogen decarboxylase inactivation in this disorder could be mediated by uroporphomethene, a competitive inhibitor, resulting from partial oxidation of uroporphyrinogen by a cytochrome P450 (*CYP1A2*) in an iron-dependent oxidative mechanism.<sup>78</sup> Liver dysfunction is common in patients with porphyria cutanea tarda, especially in association with excessive alcoholic intake, varying in sensitivity from mild cytolysis to cirrhosis. Frequency of hepatic cancer is higher in patients with porphyria cutanea tarda and cirrhosis than in those with cirrhosis alone.<sup>79,80</sup> Haemodialysis in patients with chronic renal failure can predispose to this disorder,<sup>81</sup> but in chronic renal failure and end-stage liver disease, skin blisters resembling those of porphyria cutanea tarda and often referred to as pseudoporphyria can develop.<sup>82,83</sup> The differential diagnosis between pseudoporphyria and porphyria cutanea tarda should be established by undertaking porphyrin analysis of plasma or faeces, which is abnormal only in porphyria cutanea tarda.

Once variegate porphyria and hereditary coproporphyria have been excluded and sporadic and familial porphyria cutanea tarda has been diagnosed, an initial appraisal should be made of the patients' lifestyle, alcohol and oestrogen intake, hepatitis C virus and HIV infection status, liver and renal function, iron metabolism, and haemochromatosis genotyping.<sup>84,85</sup> Alcohol intake should be prohibited. Sun avoidance, use of protective clothing, and whenever possible, use of opaque sunscreens are crucial to lessen skin symptoms in porphyria cutanea tarda and are the only way to manage skin symptoms in variegate porphyria and hereditary coproporphyria (table 3).

In patients with porphyria cutanea tarda who do not have haemochromatosis, low-dose chloroquine treatment (100–200 mg twice per week) is now widely used.<sup>86,87</sup> Chloroquine complexes porphyrins slowly mobilises them from the liver and increases their excretion into urine. Duration of treatment and relapse rates are only slightly higher without than with venesection. High-dose chloroquine treatment should be avoided because it causes a hepatitis-like syndrome in patients with porphyria cutanea tarda. Phlebotomy is the treatment of choice in such patients with haemochromatosis<sup>88</sup>—even when serum iron or ferritin concentrations are only

|                                 | Measure  | Therapy   |
|---------------------------------|--|---|
| <b>In all cases</b>             |  |   |
| Supportive                      | Photoprotection: sunlight avoidance, protective clothing, and opaque sunscreens  | ..  |
| VP and HC                       |  |   |
| Preventive                      | Prescribe drugs from safe drug list; avoid alcohol, smoking, and soft drugs (eg, cannabis and hallucinogens), dieting, and fasting | ..  |
| <b>PCT sporadic or familial</b> |  |   |
| Preventive                      | Avoid alcohol, smoking, soft drugs, and oestrogens   | ..  |
| Specific                        | Iron and porphyrin depletion   | Venesection 300–500 mL every week until remission or chloroquine 100–200 mg twice per week until remission, or both |
| <b>HEP</b>                      |  |   |
| Specific                        | Haemolytic anaemia   | Blood transfusion   |
| <b>CEP</b>                      |  |   |
| Specific                        | Haemolytic anaemia<br>Restore erythroid haem synthesis in severe cases   | Blood transfusion<br>Bone marrow transplantation  |
| <b>EPP</b>                      |  |   |
| Specific                        | Increase tolerance to sunlight<br>Hepatic failure  | β carotene 100–300 mg daily*; α-MSH analogue†<br>Liver or bone marrow transplantation                               |
| <b>X-LDPP</b>                   |  |   |
| Specific                        | Increase tolerance to sunlight<br>Hepatic failure<br>Iron depletion  | β carotene 100–300 mg daily*; α-MSH analogue†<br>Liver transplantation<br>Supply iron                               |

VP=variegate porphyria. HC=hereditary coproporphyria. PCT=porphyria cutanea tarda. HEP=hepato-erythroporphyria. CEP=congenital erythropoietic porphyria. EPP=erythropoietic protoporphyria. X-LDPP=X-linked dominant protoporphyria. \*Contraindicated in smokers. †Being assessed by Clinuvel Pharmaceuticals (Melbourne, Australia).

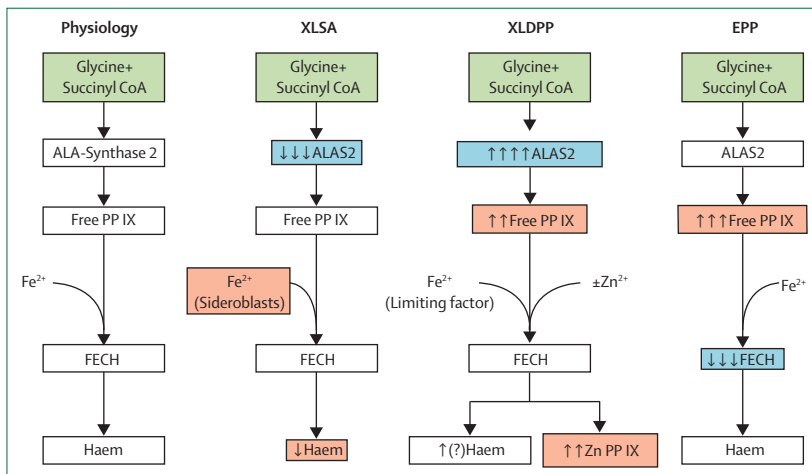
**Table 3: Types of treatment in management of cutaneous porphyrias**

slightly raised.<sup>67</sup> A unit of blood (350–500 mL) is removed every week until iron stores return to normal. This approach is continued until transferrin saturation falls below 16% or ferritin concentrations reach the low limit of normal, but can be interrupted early if haemoglobin falls below 110 g/L.<sup>89</sup> Urinary or plasma concentrations of porphyrin are monitored every 3 months and return to normal within 6 months in most cases. Clinical remission is achieved within 6–9 months.<sup>89</sup> In some severe cases, the combination of blood-letting and chloroquine therapy results in faster remission than does either treatment alone.<sup>84</sup> To detect relapse, and because of the high rate of liver disease, urinary or plasma porphyrin concentrations, iron metabolism, and liver function should be assessed yearly. In porphyria cutanea tarda with chronic renal failure, erythropoietin supplementation is given because it mobilises iron in haemoglobin synthesis, thereby depleting excessive body-iron stores.<sup>90,91</sup>

#### Acute painful photosensitive porphyrias

Erythropoietic protoporphyria is an inherited disorder that is caused by partial deficiency in mitochondrial





**Figure 6: Physiopathological pathways of acute painful photosensitive porphyrias**  
EPP=erythropoietic protoporphyria. XLDPP=X-linked dominant protoporphyria. XLSA=X-linked sideroblastic anaemia. ALA=5-aminolaevulinic acid. PPIX=FECH=mitochondrial ferrochelatase. ALAS2=ALA synthase.

ferrochelatase, the terminal enzyme of haem biosynthesis (figures 1 and 6). Accumulation of free protoporphyrin, mainly in erythrocytes and secondarily in other tissues (skin and liver) or biological fluids (bile and faeces), leads to painful photosensitivity and potential liver complications. The most common clinical manifestation is seasonal lifelong acute photosensitivity of sun-exposed skin.<sup>92</sup> Photosensitivity develops in early childhood, but in rare cases symptoms manifest in adulthood. Skin symptoms of erythropoietic protoporphyria include burning, stinging, and pruritus in sun-exposed skin. Phototoxic reactions take place within minutes of sun exposure, and acute burning pain is ameliorated by application of cold water. Mild symptoms such as oedema and erythema arise immediately after sun exposure, and chronic lesions such as thickening of the hand skin and wax-like scarring on the face are common. Seasonal palmar keratoderma has been reported<sup>93</sup> in some patients who are compound heterozygotes or homozygotes for *FECH* mutations. Many patients have a slight microcytic, hypochromic anaemia.<sup>94–96</sup> Although erythropoietic protoporphyria is generally a benign disease, biochemical evidence of liver dysfunction can be identified in 10–20% of these patients. Gallstones can form from protoporphyrin, and these patients are at increased risk of cholelithiasis. In about 2%, a rapidly progressing and irreversible cholestatic liver failure develops.<sup>92,97,98</sup> Liver dysfunction is caused by accumulation of protoporphyrin in hepatocytes and bile canaliculi, resulting in cell damage, cholestasis, cytolysis, and further retention of protoporphyrin.

The mode of erythropoietic protoporphyria inheritance is complex but is almost always associated with two molecular defects. In about 94% of patients with overt disease, clinical expression usually requires coinheritance of a private *FECH* mutation<sup>99</sup> that is trans to a hypomorphic *FECH\*IVS3-48C* allele. The effect of this

allele is to lower mitochondrial ferrochelatase activity below a crucial threshold of about 35%.<sup>100–103</sup> About 4% of families have this disorder with either homozygous or compound heterozygous *FECH* mutations, and these homo-allelic or hetero-allelic patients have a raised risk of severe liver disease.<sup>104</sup> Finally, acquired somatic *FECH* mutations have been described<sup>105,106</sup> in patients who developed erythropoietic protoporphyria in association with myelodysplasia or myeloproliferative disorder after age 40 years.

Because protoporphyrin is strictly lipophilic, excretion of porphyrin in urine does not increase. Diagnosis is based on a large increase in free protoporphyrin concentrations in erythrocytes.<sup>107</sup> Plasma porphyrin fluorescence assay shows a characteristic peak at 634 nm in symptomatic patients. Mitochondrial ferrochelatase enzyme activity, measured in nucleated cells, is reduced to 10–35% of the normal value in symptomatic patients and about 50% in asymptomatic carriers.<sup>101</sup> Screening for mutation and for the hypomorphic *IVS3-48C/T* identifies symptom-free family members and allows definition of the mode of inheritance in that family.<sup>100</sup>

Protection from sunlight is the mainstay of erythropoietic protoporphyria management. Special clothes, opaque topical sunscreens, or UVB phototherapy can ameliorate photointolerance.<sup>108</sup> Afamelanotide, an  $\alpha$  melanocyte-stimulating hormone analogue, has been suggested as a means to induce photo-protective epidermal melanin formation.<sup>109</sup> Oral  $\beta$  carotene (75–200 mg per day) improves light tolerance in about a third of patients, but it is contraindicated in smokers (table 3).<sup>108</sup> Prediction of which patients will develop severe liver disease is impossible, and management should include yearly biochemical assessment of liver function.<sup>110</sup> When liver dysfunction develops, treatment with cholestyramine (which depletes hepatic protoporphyrin) or activated charcoal (which binds protoporphyrin in the gut) should be attempted, but their effectiveness remains to be proven.<sup>110</sup> When liver failure is advanced, transplantation is the only treatment likely to ensure survival.<sup>110,111</sup> During surgery, protection with a physical barrier and modification of surgical lighting (yellow filter) are recommended to reduce potential phototoxic injury of intra-abdominal organs.<sup>112</sup> After liver transplantation, protoporphyrin might accumulate in the donor liver, which shows the key role of bone marrow in protoporphyrin overproduction. Concomitant liver and bone-marrow transplantation should be undertaken to prevent relapse of liver disease;<sup>113</sup> however, the exact role of the cotransplantation remains to be investigated.

A previously unrecognised form of porphyria<sup>114</sup> has a clinical presentation very similar to that of erythropoietic protoporphyria, with huge amounts of protoporphyrin in erythrocytes, of which about 40% is bound to zinc, but without ferrochelatase deficiency. This new porphyria, called X-linked dominant erythropoietic protoporphyria,

results from increased activity of ALAS2 attributable to gain-of-function deletions in ALAS2 (figure 6). All other previously described mutations in ALAS2 are loss-of-function mutations that cause recessive X-linked sideroblastic anaemia. ALAS2 gain of function leads to production of protoporphyrin in excess of the amount needed for haemoglobin synthesis, and in quantities sufficient to cause photosensitivity and liver damage—despite healthy mitochondrial ferrochelatase activity. Supportive and preventive treatments are similar to those for erythropoietic protoporphyria.

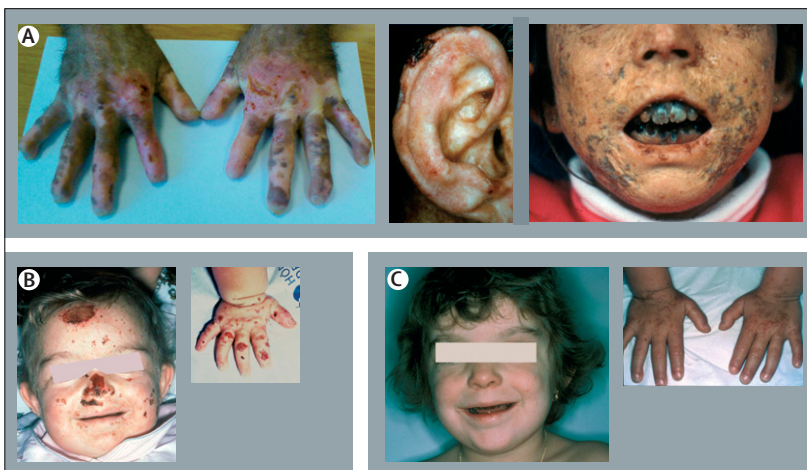
### Rare recessive porphyrias

#### Congenital erythropoietic porphyria

Congenital erythropoietic porphyria (or Günther disease) is the most frequent of the rare recessive porphyrias. Inheritance is autosomal recessive, and the disorder results from a pronounced deficiency of uroporphyrinogen III synthase enzymatic activity (UROS). The enzymatic defect causes specific overproduction and excretion of the non-physiological and pathogenic isomer I of uroporphyrin and coproporphyrin (figures 1 and 3).<sup>115</sup> Molecular study<sup>116,117</sup> of the UROS gene in these patients has identified various mutations. However, a common missense mutation, *p.Cys73Arg*, is identified in 40% of disease alleles of white people.<sup>118</sup> Moreover, congenital erythropoietic porphyria features attributable to UROS deficiency that is secondary to a *GATA-1* erythroid-specific transcription-factor gene mutation have also been reported (table 1).<sup>119</sup> Clinical features combine cutaneous photosensitivity and chronic haemolysis, the severity of which varies.

Most patients have severe photosensitivity, leading to bullae, scarring, and eventually disfigurement of the light-exposed parts of the body such as hands, ears, nose, and eyelids. Ocular involvement includes chronic ulcerative keratitis and corneal scarring.<sup>55</sup> Secondary infections of lesions can lead to scarring, deformities, and loss of fingernails and digits. Erythrodontia (figure 7), osteodystrophia, combining osteolysis and osteoporosis, and hypercellular bone marrow are present in almost all patients. Red fluorescent urine in nappies provides an easy early diagnosis. Mild-to-severe haemolysis and hypersplenism are suggestive of impaired haem metabolism in erythrocytes. Phenotypic heterogeneity is typical of congenital erythropoietic porphyria. Adult late-onset forms show either a mild phenotype often restricted to skin photosensitivity because of a mild inherited UROS mutations or, in older patients, a congenital erythropoietic porphyria-like syndrome as a complication of myeloid malignancy, which precedes the onset of skin lesions.<sup>120</sup>

Extremely severe forms of congenital erythropoietic porphyria, starting during embryogenesis, are dominated by severe haemolytic anaemia that leads to hydrops fetalis and death in utero. The earliest possible diagnosis is advisable because special care should be taken with



**Figure 7:** Clinical presentation of congenital erythropoietic porphyria (Günther's disease). Severe presentation in adults (A); severe presentation in a newborn before (B) and 2 years after (C) bone marrow transplantation with persistence of erythrodontia.

affected babies to avoid phototherapy for treatment of neonatal jaundice. Allogeneic bone-marrow transplantation is the only curative treatment and has been successful in several patients with moderate-to-severe disease (figure 7).<sup>120–122</sup> The crucial supportive treatment for congenital erythropoietic porphyria is based on protection from sunlight and UV exposure, associated with meticulous skin care (table 3). Anaemia can be so severe that some patients are transfusion-dependent. Splenectomy can reduce need for transfusions.<sup>121,123</sup> Gene-based therapy is being investigated.<sup>124</sup>

#### Hepatoerythropoietic porphyria

Hepatoerythropoietic porphyria is caused by a homozygous or compound heterozygous deficiency of uroporphyrinogen decarboxylase.<sup>125</sup> Only about 34 cases of this disorder have been reported. It is predominantly a hepatic porphyria that rarely resembles congenital erythropoietic porphyria clinically and tends to present in infancy or childhood with red urine, blistering skin lesions, hypertrichosis, and scarring (figure 5). Sclerodermoid skin changes are the predominant feature in some cases. Erythrocyte porphyrin concentrations are increased, but protoporphyrins predominate. Some patients also have haemolytic anaemia and splenomegaly. However, biochemical findings in hepatoerythropoietic porphyria resemble those reported for porphyria cutanea tarda (table 1). Treatment is based on sun avoidance measures and blood-letting and chloroquine are not effective in this disorder.

#### Rare recessive acute hepatic porphyrias

The variants of this subgroup are 5-aminolaevulinic acid dehydratase porphyria, acute intermittent porphyria, variegate porphyria, and hereditary coproporphyria. In these rare variants that manifest in infants or early childhood, orange urine in nappies could suggest

porphyrias (figure 3). Five homozygous cases of acute intermittent porphyria have presented with phenotypes of variable severity. The clinical situation is wholly different from that of dominant acute intermittent porphyria—affected children have pencephaly, severe developmental retardation, neurological defects, cataract, psychomotor retardation, ataxia, and convulsions.<sup>126,127</sup>

Recessive variegate porphyria with cutaneous lesions accompanied by skeletal abnormalities of the hand has been reported in about 15 individuals.<sup>128–130</sup> Short stature, mental retardation, and convulsions also arise but less frequently than lesions or hand abnormalities. Two different types of homozygous hereditary coproporphyrin cases have been described<sup>131–133</sup> with a documented genotype-phenotype relation. In the first type, patients were small and showed skin photosensitivity, developmental retardation, neurological defects, and psychomotor retardation.<sup>131</sup> In the second type, so-called harderoporphyria, patients presented with intense jaundice and haemolytic anaemia at birth without neurological symptoms.<sup>132,133</sup> The pattern of faecal porphyrin excretion was not typical, with large amounts of harderoporphyrin in addition to coproporphyrin.

Six cases of recessive 5-aminolaevulinic acid dehydratase porphyria have been reported and genetically substantiated as *ALAD* mutations.<sup>134</sup> The disease can manifest in childhood or in adulthood with severe neurological symptoms that have features of chronic neuropathy sometimes associated with acute attacks.<sup>135</sup> This disorder subtype is characterised by greatly increased excretion of 5-aminolaevulinic acid and coproporphyrin (table 1) in urine, accompanied by low 5-aminolaevulinic acid dehydratase activity measured in erythrocytes.<sup>136</sup> In hereditary tyrosinaemia type I, symptoms of this disorder develop as a result of accumulation of succinylacetone,<sup>137</sup> the most potent inhibitor of 5-aminolaevulinic acid dehydratase in the liver, which is identified in urine and blood of patients. As a result, about 40% of these children have symptoms resembling attacks of acute porphyria.<sup>138</sup> Treatment is the same as that for acute attacks and is effective in some but not all cases. Liver transplantation in these patients has little effect on the symptoms or biochemical profile, suggesting irreversible neural damage.<sup>139</sup> Future attacks are prevented by avoidance of agents known to stimulate *ALAS1* activity and also those known to inhibit 5-aminolaevulinic acid dehydratase activity (eg, lead).<sup>138</sup>

### European porphyria network

The European Porphyria Network (EPNET) is a collaborative project between European porphyria centres that was established to provide improved health care for patients and their families. It has been partly funded by the EU Commission Public Health Executive Agency (PHEA). The overall aim is to develop a common approach to diagnosis and clinical management of porphyrias so that patients, their families, and health-care

professionals can benefit from access to evidence-based, consensus-agreed information in their own languages through easily accessible support. EPNET was developed after successful establishment of a collaborative research initiative European Porphyria Initiative (EPI) on the acute porphyrias between reference porphyria centres from many European countries<sup>140</sup> and the development of a porphyria drug database.

#### Contributors

HP contributed to editing the text on hepatic porphyrias and designed the figures. LG contributed to editing the section on erythropoietic porphyrias, and J-CD coordinated the study design and was the head supervisor. All authors contributed to writing the report.

#### Conflicts of interest

We declare that we have no conflicts of interest.

#### Acknowledgments

We thank Bernard Grandchamp, Carole Beaumont, Mike Badminton, and George Elder for informative and helpful discussions related to clinical and physiopathological details in genetic and haematology; and Jean-Pierre Laigneau for graphical support. All authors were supported by Grant Public Health and Consumer Protection Directorate Public Health Executive Agency from the European Commission, Brussels, Belgium, and grant number ANR-07-MRAR-008-01 from ANR-GIS Maladies rares, Paris, France.

#### References

- Anderson KE, Sassa SS, Bishop DF, Desnick RJ. Disorders of heme biosynthesis: X-linked sideroblastic anemia and the porphyrias. In: Scriver CR, Beaudet AL, Sly WS, Valle, D, eds. *The metabolic basis of inherited disease*, 8th edn. New York: McGraw-Hill, 2001.
- Moore MR, McColl KM, Rimington C, Goldberg A. *Disorders of porphyrin metabolism*. New York: Plenum Publishing Corporation, 1987.
- Bishop DF, Henderson AS, Astrin KH. Human delta-aminolevulinic acid synthase: assignment of the housekeeping gene to 3p21 and the erythroid-specific gene to the X chromosome. *Genomics* 1990; **7**: 207–14.
- Fraser DJ, Podvinec M, Kaufmann MR, Meyer UA. Drugs mediate the transcriptional activation of the 5-aminolevulinic acid synthase (*ALAS1*) gene via the chicken xenobiotic-sensing nuclear receptor (CXR). *J Biol Chem* 2002; **277**: 34717–26.
- Thunell S. (Far) Outside the box: genomic approach to acute porphyria. *Physiol Res* 2006; **55** (suppl 2): 43–66.
- Smith SJ, Cox TM. Translational control of erythroid delta-aminolevulinic acid synthase in immature human erythroid cells by heme. *Cell Mol Biol (Noisy-le-grand)* 1997; **43**: 103–14.
- Schneider-Yin X, Hergersberg M, Goldgar DE, et al. Ancestral founder of mutation W283X in the porphobilinogen deaminase gene among acute intermittent porphyria patients. *Hum Hered* 2002; **54**: 69–81.
- Floderus Y, Shoolingin-Jordan PM, Harper P. Acute intermittent porphyria in Sweden. Molecular, functional and clinical consequences of some new mutations found in the porphobilinogen deaminase gene. *Clin Genet* 2002; **62**: 288–97.
- Meissner PN, Dailey TA, Hift RJ, et al. A R59W mutation in human protoporphyrinogen oxidase results in decreased enzyme activity and is prevalent in South Africans with variegate porphyria. *Nat Genet* 1996; **13**: 95–97.
- Bylesjo I, Wikberg A, Andersson C. Clinical aspects of acute intermittent porphyria in northern Sweden: a population-based study. *Scand J Clin Lab Invest* 2009; **69**: 612–18.
- Andersson C, Innala E, Backstrom T. Acute intermittent porphyria in women: clinical expression, use and experience of exogenous sex hormones. A population-based study in northern Sweden. *J Intern Med* 2003; **254**: 176–83.
- Mustajoki P, Nordmann Y. Early administration of heme arginate for acute porphyric attacks. *Arch Intern Med* 1993; **153**: 2004–08.
- Crimlisk HL. The little imitator—porphyria: a neuropsychiatric disorder. *J Neurol Neurosurg Psychiatry* 1997; **62**: 319–28.

- 14 Hift RJ, Meissner PN. An analysis of 112 acute porphyric attacks in Cape Town, South Africa: evidence that acute intermittent porphyria and variegate porphyria differ in susceptibility and severity. *Medicine (Baltimore)* 2005; **84**: 48–60.
- 15 Kauppinen R, von und zu Fraunberg M. Molecular and biochemical studies of acute intermittent porphyria in 196 patients and their families. *Clin Chem* 2002; **48**: 1891–900.
- 16 Lim CK, Peters TJ. Urine and faecal porphyrin profiles by reversed-phase high-performance liquid chromatography in the porphyrias. *Clin Chim Acta* 1984; **139**: 55–63.
- 17 Aarsand AK, Petersen PH, Sandberg S. Estimation and application of biological variation of urinary delta-aminolevulinic acid and porphobilinogen in healthy individuals and in patients with acute intermittent porphyria. *Clin Chem* 2006; **52**: 650–56.
- 18 Hift RJ, Davidson BP, van der Hooft C, Meissner DM, Meissner PN. Plasma fluorescence scanning and fecal porphyrin analysis for the diagnosis of variegate porphyria: precise determination of sensitivity and specificity with detection of protoporphyrinogen oxidase mutations as a reference standard. *Clin Chem* 2004; **50**: 915–23.
- 19 Da Silva V, Simonin S, Deybach JC, Puy H, Nordmann Y. Variegate porphyria: diagnostic value of fluorometric scanning of plasma porphyrins. *Clin Chim Acta* 1995; **238**: 163–68.
- 20 Kuhnel A, Gross U, Doss MO. Hereditary coproporphyria in Germany: clinical-biochemical studies in 53 patients. *Clin Biochem* 2000; **33**: 465–73.
- 21 Hindmarsh JT, Oliveras L, Greenway DC. Biochemical differentiation of the porphyrias. *Clin Biochem* 1999; **32**: 609–19.
- 22 Allen KR, Whatley SD, Degg TJ, Barth JH. Hereditary coproporphyria: comparison of molecular and biochemical investigations in a large family. *J Inher Metab Dis* 2005; **28**: 779–85.
- 23 Puy H, Deybach JC, Lamoril J, et al. Molecular epidemiology and diagnosis of PBG deaminase gene defects in acute intermittent porphyria. *Am J Hum Genet* 1997; **60**: 1373–83.
- 24 Rosipal R, Lamoril J, Puy H, et al. Systematic analysis of coproporphyrinogen oxidase gene defects in hereditary coproporphyria and mutation update. *Hum Mutat* 1999; **13**: 44–53.
- 25 Whatley SD, Puy H, Morgan RR, et al. Variegate porphyria in Western Europe: identification of PPOX gene mutations in 104 families, extent of allelic heterogeneity, and absence of correlation between phenotype and type of mutation. *Am J Hum Genet* 1999; **65**: 984–94.
- 26 Lamoril J, Puy H, Whatley SD, et al. Characterization of mutations in the CPO gene in British patients demonstrates absence of genotype-phenotype correlation and identifies relationship between hereditary coproporphyria and harderoporphyria. *Am J Hum Genet* 2001; **68**: 1130–38.
- 27 Grandchamp B, Picat C, Kauppinen R, et al. Molecular analysis of acute intermittent porphyria in a Finnish family with normal erythrocyte porphobilinogen deaminase. *Eur J Clin Invest* 1989; **19**: 415–18.
- 28 Whatley SD, Mason NG, Woolf JR, Newcombe RG, Elder GH, Badminton MN. Diagnostic strategies for autosomal dominant acute porphyrias: retrospective analysis of 467 unrelated patients referred for mutational analysis of the HMBS, CPOX, or PPOX gene. *Clin Chem* 2009; **55**: 1406–14.
- 29 Meyer UA, Schuurmans MM, Lindberg RL. Acute porphyrias: pathogenesis of neurological manifestations. *Semin Liver Dis* 1998; **18**: 43–52.
- 30 Sima AA, Kennedy JC, Blakeslee D, Robertson DM. Experimental porphyric neuropathy: a preliminary report. *Can J Neurol Sci* 1981; **8**: 105–13.
- 31 Soonawalla ZF, Orug T, Badminton MN, et al. Liver transplantation as a cure for acute intermittent porphyria. *Lancet* 2004; **363**: 705–06.
- 32 Podvinec M, Handschin C, Looser R, Meyer UA. Identification of the xenosensors regulating human 5-aminolevulinic synthase. *Proc Natl Acad Sci USA* 2004; **101**: 9127–32.
- 33 Lip GY, McColl KE, Goldberg A, Moore MR. Smoking and recurrent attacks of acute intermittent porphyria. *BMJ* 1991; **302**: 507.
- 34 Handschin C, Lin J, Rhee J, et al. Nutritional regulation of hepatic heme biosynthesis and porphyria through PGC-1alpha. *Cell* 2005; **122**: 505–15.
- 35 Degenhardt T, Vaisanen S, Rakhshandehroo M, Kersten S, Carlberg C. Peroxisome proliferator-activated receptor alpha controls hepatic heme biosynthesis through ALAS1. *J Mol Biol* 2009; **388**: 225–38.
- 36 Delaby C, To-Figueras J, Deybach JC, Casamitjana R, Puy H, Herrero C. Role of two nutritional hepatic markers (insulin-like growth factor 1 and transthyretin) in the clinical assessment and follow-up of AIP patients. *J Intern Med* 2009; **266**: 277–85.
- 37 Kauppinen R, Mustajoki P. Prognosis of acute porphyria: occurrence of acute attacks, precipitating factors, and associated diseases. *Medicine (Baltimore)* 1992; **71**: 1–13.
- 38 Bonkovsky HL, Healey JF, Lourie AN, Gerron GG. Intravenous heme-albumin in acute intermittent porphyria: evidence for repletion of hepatic hemoproteins and regulatory heme pools. *Am J Gastroenterol* 1991; **86**: 1050–56.
- 39 Anderson KE, Bloomer JR, Bonkovsky HL, et al. Recommendations for the diagnosis and treatment of the acute porphyrias. *Ann Intern Med* 2005; **142**: 439–50.
- 40 Mustajoki P, Tenhunen R, Pierach C, Volin L. Heme in the treatment of porphyrias and hematological disorders. *Semin Hematol* 1989; **26**: 1–9.
- 41 Siegert SW, Holt RJ. Physicochemical properties, pharmacokinetics, and pharmacodynamics of intravenous hematin: a literature review. *Adv Ther* 2008; **25**: 842–57.
- 42 Anderson KE, Bonkovsky HL, Bloomer JR, Shedlofsky SI. Reconstitution of hematin for intravenous infusion. *Ann Intern Med* 2006; **144**: 537–38.
- 43 Badminton MN, Deybach JC. Treatment of an acute attack of porphyria during pregnancy. *Eur J Neurol* 2006; **13**: 668–69.
- 44 Pischik E, Kauppinen R. Can pregnancy stop cyclical attacks of porphyria? *Am J Med* 2006; **119**: 88–90.
- 45 Seth AK, Badminton MN, Mirza D, Russell S, Elias E. Liver transplantation for porphyria: who, when, and how? *Liver Transpl* 2007; **13**: 1219–27.
- 46 Doss MO, Kuhnel A, Gross U. Alcohol and porphyrin metabolism. *Alcohol Alcohol* 2000; **35**: 109–25.
- 47 Thunell S, Pomp E, Brun A. Guide to drug porphyrinogenicity prediction and drug prescription in the acute porphyrias. *Br J Clin Pharmacol* 2007; **64**: 668–79.
- 48 Andersson C, Lithner F. Hypertension and renal disease in patients with acute intermittent porphyria. *J Intern Med* 1994; **236**: 169–75.
- 49 Kauppinen R, Mustajoki P. Acute hepatic porphyria and hepatocellular carcinoma. *Br J Cancer* 1988; **57**: 117–20.
- 50 Andant C, Puy H, Bogard C, et al. Hepatocellular carcinoma in patients with acute hepatic porphyria: frequency of occurrence and related factors. *J Hepatol* 2000; **32**: 933–39.
- 51 Andant C, Puy H, Faivre J, Deybach JC. Acute hepatic porphyrias and primary liver cancer. *N Engl J Med* 1998; **338**: 1853–54.
- 52 Andersson C, Bjersing L, Lithner F. The epidemiology of hepatocellular carcinoma in patients with acute intermittent porphyria. *J Intern Med* 1996; **240**: 195–201.
- 53 Laiwah AA, Mactier R, McColl KE, Moore MR, Goldberg A. Early-onset chronic renal failure as a complication of acute intermittent porphyria. *Q J Med* 1983; **52**: 92–98.
- 54 Murphy GM. The cutaneous porphyrias: a review. The British Photodermatology Group. *Br J Dermatol* 1999; **140**: 573–81.
- 55 Altiparmak UE, Oflu Y, Kocaoglu FA, Katircioglu YA, Duman S. Ocular complications in 2 cases with porphyria. *Cornea* 2008; **27**: 1093–96.
- 56 Poh-Fitzpatrick MB. Molecular and cellular mechanisms of porphyrin photosensitization. *Photodermatol* 1986; **3**: 148–57.
- 57 Timonen K, Niemi KM, Mustajoki P. Skin morphology in porphyria cutanea tarda does not improve despite clinical remission. *Clin Exp Dermatol* 1991; **16**: 355–58.
- 58 Timonen K, Niemi KM, Mustajoki P, Tenhunen R. Skin changes in variegate porphyria. Clinical, histopathological, and ultrastructural study. *Arch Dermatol Res* 1990; **282**: 108–14.
- 59 Maynard B, Peters MS. Histologic and immunofluorescence study of cutaneous porphyrias. *J Cutan Pathol* 1992; **19**: 40–47.
- 60 Hindmarsh JT, Oliveras L, Greenway DC. Plasma porphyrins in the porphyrias. *Clin Chem* 1999; **45**: 1070–76.
- 61 Elder GH. Porphyria cutanea tarda. *Semin Liver Dis* 1998; **18**: 67–75.
- 62 Elder GH. Identification of a group of tetracarboxylate porphyrins, containing one acetate and three propionate-substituents, in faeces from patients with symptomatic cutaneous hepatic porphyria and from rats with porphyria due to hexachlorobenzene. *Biochem J* 1972; **126**: 877–91.

- 63 de Verneuil H, Nordmann Y, Phung N, et al. Familial and sporadic porphyria cutanea: two different diseases. *Int J Biochem* 1978; **9**: 927–31.
- 64 Elder GH, Lee GB, Tovey JA. Decreased activity of hepatic uroporphyrinogen decarboxylase in sporadic porphyria cutanea tarda. *N Engl J Med* 1978; **299**: 274–78.
- 65 Aarsand AK, Boman H, Sandberg S. Familial and sporadic porphyria cutanea tarda: characterization and diagnostic strategies. *Clin Chem* 2009; **55**: 795–803.
- 66 Badenas C, To-Figuera J, Phillips JD, Warby CA, Munoz C, Herrero C. Identification and characterization of novel uroporphyrinogen decarboxylase gene mutations in a large series of porphyria cutanea tarda patients and relatives. *Clin Genet* 2009; **75**: 346–53.
- 67 Bulaj ZJ, Phillips JD, Ajioka RS, et al. Hemochromatosis genes and other factors contributing to the pathogenesis of porphyria cutanea tarda. *Blood* 2000; **95**: 1565–71.
- 68 Gisbert JP, Garcia-Buey L, Pajares JM, Moreno-Otero R. Prevalence of hepatitis C virus infection in porphyria cutanea tarda: systematic review and meta-analysis. *J Hepatol* 2003; **39**: 620–27.
- 69 Fargion S, Piperno A, Cappellini MD, et al. Hepatitis C virus and porphyria cutanea tarda: evidence of a strong association. *Hepatology* 1992; **16**: 1322–26.
- 70 Egger NG, Goeger DE, Payne DA, Miskovsky EP, Weinman SA, Anderson KE. Porphyria cutanea tarda: multiplicity of risk factors including HFE mutations, hepatitis C, and inherited uroporphyrinogen decarboxylase deficiency. *Dig Dis Sci* 2002; **47**: 419–26.
- 71 Roberts AG, Whatley SD, Morgan RR, Worwood M, Elder GH. Increased frequency of the haemochromatosis Cys282Tyr mutation in sporadic porphyria cutanea tarda. *Lancet* 1997; **349**: 321–23.
- 72 Roberts AG, Whatley SD, Nicklin S, et al. The frequency of hemochromatosis-associated alleles is increased in British patients with sporadic porphyria cutanea tarda. *Hepatology* 1997; **25**: 159–61.
- 73 Ellervik C, Birgens H, Tybjaerg-Hansen A, Nordestgaard BG. Hemochromatosis genotypes and risk of 31 disease endpoints: meta-analyses including 66,000 cases and 226,000 controls. *Hepatology* 2007; **46**: 1071–80.
- 74 Dabrowska E, Jablonska-Kaszewska I, Bielański KP, Falkiewicz B. Influence of hepatitis C virus (HCV) infection on porphyrin and iron metabolism in porphyria cutanea tarda (PCT) patients. *Med Sci Monit* 2001; **7** (suppl 1): 190–96.
- 75 Cruz-Rojo J, Fontanellas A, Moran-Jimenez MJ, et al. Precipitating/aggravating factors of porphyria cutanea tarda in Spanish patients. *Cell Mol Biol (Noisy-le-grand)* 2002; **48**: 845–52.
- 76 Lamoril J, Andant C, Gouya L, et al. Hemochromatosis (HFE) and transferrin receptor-1 (TFR1) genes in sporadic porphyria cutanea tarda (spPCT). *Cell Mol Biol (Noisy-le-grand)* 2002; **48**: 33–41.
- 77 Ajioka RS, Phillips JD, Weiss RB, et al. Down-regulation of hepcidin in porphyria cutanea tarda. *Blood* 2008; **112**: 4723–28.
- 78 Phillips JD, Bergonia HA, Reilly CA, Franklin MR, Kushner JP. A porphomethene inhibitor of uroporphyrinogen decarboxylase causes porphyria cutanea tarda. *Proc Natl Acad Sci USA* 2007; **104**: 5079–84.
- 79 Siersema PD, ten Kate FJ, Mulder PG, Wilson JH. Hepatocellular carcinoma in porphyria cutanea tarda: frequency and factors related to its occurrence. *Liver* 1992; **12**: 56–61.
- 80 Gisbert JP, Garcia-Buey L, Alonso A, et al. Hepatocellular carcinoma risk in patients with porphyria cutanea tarda. *Eur J Gastroenterol Hepatol* 2004; **16**: 689–92.
- 81 Shieh S, Cohen JL, Lim HW. Management of porphyria cutanea tarda in the setting of chronic renal failure: a case report and review. *J Am Acad Dermatol* 2000; **42**: 645–52.
- 82 Cordova KB, Oberg TJ, Malik M, Robinson-Bostom L. Dermatologic conditions seen in end-stage renal disease. *Semin Dial* 2009; **22**: 45–55.
- 83 Poh-Fitzpatrick MB. Porphyria, pseudoporphyria, pseudopseudoporphyria...? *Arch Dermatol* 1986; **122**: 403–04.
- 84 Sarkany RP. The management of porphyria cutanea tarda. *Clin Exp Dermatol* 2001; **26**: 225–32.
- 85 Lecha M, Herrero C, Ozalla D. Diagnosis and treatment of the hepatic porphyrias. *Dermatol Ther* 2003; **16**: 65–72.
- 86 Egger NG, Goeger DE, Anderson KE. Effects of chloroquine in hematoporphyrin-treated animals. *Chem Biol Interact* 1996; **102**: 69–78.
- 87 Valls V, Ena J, Enriquez-De-Salamanca R. Low-dose oral chloroquine in patients with porphyria cutanea tarda and low-moderate iron overload. *J Dermatol Sci* 1994; **7**: 169–75.
- 88 Ippen H. Treatment of porphyria cutanea tarda by phlebotomy. *Semin Hematol* 1977; **14**: 253–59.
- 89 Badminton MN, Elder GH. Management of acute and cutaneous porphyrias. *Int J Clin Pract* 2002; **56**: 272–78.
- 90 Anderson KE, Goeger DE, Carson RW, Lee SM, Stead RB. Erythropoietin for the treatment of porphyria cutanea tarda in a patient on long-term hemodialysis. *N Engl J Med* 1990; **322**: 315–17.
- 91 Peces R, Enriquez de Salamanca R, Fontanellas A, et al. Successful treatment of haemodialysis-related porphyria cutanea tarda with erythropoietin. *Nephrol Dial Transplant* 1994; **9**: 433–35.
- 92 Murphy GM. Diagnosis and management of the erythropoietic porphyrias. *Dermatol Ther* 2003; **16**: 57–64.
- 93 Holme SA, Whatley SD, Roberts AG, et al. Seasonal palmar keratoderma in erythropoietic protoporphyria indicates autosomal recessive inheritance. *J Invest Dermatol* 2009; **129**: 599–605.
- 94 Holme SA, Worwood M, Anstey AV, Elder GH, Badminton MN. Erythropoiesis and iron metabolism in dominant erythropoietic protoporphyria. *Blood* 2007; **110**: 4108–10.
- 95 Lyoumi S, Abitbol M, Andrieu V, et al. Increased plasma transferrin, altered body iron distribution, and microcytic hypochromic anemia in ferrochelatase-deficient mice. *Blood* 2007; **109**: 811–18.
- 96 Delaby C, Lyoumi S, Ducamp S, et al. Excessive erythrocyte ppx influences the hematologic status and iron metabolism in patients with dominant erythropoietic protoporphyria. *Cell Mol Biol (Noisy-le-grand)* 2009; **55**: 45–52.
- 97 Schneider-Yin X, Gouya L, Meier-Weinand A, Deybach JC, Minder EI. New insights into the pathogenesis of erythropoietic protoporphyria and their impact on patient care. *Eur J Pediatr* 2000; **159**: 719–25.
- 98 Doss MO, Frank M. Hepatobiliary implications and complications in protoporphyria, a 20-year study. *Clin Biochem* 1989; **22**: 223–29.
- 99 Rufenacht UB, Gouya L, Schneider-Yin X, et al. Systematic analysis of molecular defects in the ferrochelatase gene from patients with erythropoietic protoporphyria. *Am J Hum Genet* 1998; **62**: 1341–52.
- 100 Gouya L, Martin-Schmitt C, Robreau AM, et al. Contribution of a common single-nucleotide polymorphism to the genetic predisposition for erythropoietic protoporphyria. *Am J Hum Genet* 2006; **78**: 2–14.
- 101 Gouya L, Puy H, Robreau AM, et al. The penetrance of dominant erythropoietic protoporphyria is modulated by expression of wildtype FECH. *Nat Genet* 2002; **30**: 27–28.
- 102 Gouya L, Puy H, Lamoril J, et al. Inheritance in erythropoietic protoporphyria: a common wild-type ferrochelatase allelic variant with low expression accounts for clinical manifestation. *Blood* 1999; **93**: 2105–10.
- 103 Gouya L, Deybach JC, Lamoril J, et al. Modulation of the phenotype in dominant erythropoietic protoporphyria by a low expression of the normal ferrochelatase allele. *Am J Hum Genet* 1996; **58**: 292–99.
- 104 Whatley SD, Mason NG, Khan M, et al. Autosomal recessive erythropoietic protoporphyria in the United Kingdom: prevalence and relationship to liver disease. *J Med Genet* 2004; **41**: e105.
- 105 Sarkany RP, Ross G, Willis F. Acquired erythropoietic protoporphyria as a result of myelodysplasia causing loss of chromosome 18. *Br J Dermatol* 2006; **155**: 464–66.
- 106 Goodwin RG, Kell WJ, Laidler P, et al. Photosensitivity and acute liver injury in myeloproliferative disorder secondary to late-onset protoporphyria caused by deletion of a ferrochelatase gene in hematopoietic cells. *Blood* 2006; **107**: 60–62.
- 107 Cox TM. Erythropoietic protoporphyria. *J Inher Metab Dis* 1997; **20**: 258–69.
- 108 Minder EI, Schneider-Yin X, Steurer J, Bachmann LM. A systematic review of treatment options for dermal photosensitivity in erythropoietic protoporphyria. *Cell Mol Biol* 2009; **55**: 84–97.
- 109 Harms J, Lautenschlager S, Minder CE, Minder EI. An alpha-melanocyte-stimulating hormone analogue in erythropoietic protoporphyria. *N Engl J Med* 2009; **360**: 306–07.
- 110 Anstey AV, Hift RJ. Liver disease in erythropoietic protoporphyria: insights and implications for management. *Postgrad Med J* 2007; **83**: 739–48.

- 111 McGuire BM, Bonkovsky HL, Carithers RL Jr, et al. Liver transplantation for erythropoietic protoporphyria liver disease. *Liver Transpl* 2005; **11**: 1590–96.
- 112 Wahlin S, Srikanthan N, Hamre B, Harper P, Brun A. Protection from phototoxic injury during surgery and endoscopy in erythropoietic protoporphyria. *Liver Transpl* 2008; **14**: 1340–46.
- 113 Rand EB, Bunin N, Cochran W, Ruchelli E, Olthoff KM, Bloomer JR. Sequential liver and bone marrow transplantation for treatment of erythropoietic protoporphyria. *Pediatrics* 2006; **118**: e1896–99.
- 114 Whatley SD, Ducamp S, Gouya L, et al. C-terminal deletions in the ALAS2 gene lead to gain of function and cause X-linked dominant protoporphyria without anemia or iron overload. *Am J Hum Genet* 2008; **83**: 408–14.
- 115 Fritsch C, Bolsen K, Ruzicka T, Goerz G. Congenital erythropoietic porphyria. *J Am Acad Dermatol* 1997; **36**: 594–610.
- 116 Fontanellas A, Bensidhoum M, Enriquez de Salamanca R, Moruno Tirado A, de Verneuil H, Ged C. A systematic analysis of the mutations of the uroporphyrinogen III synthase gene in congenital erythropoietic porphyria. *Eur J Hum Genet* 1996; **4**: 274–82.
- 117 Desnick RJ, Glass IA, Xu W, Solis C, Astrin KH. Molecular genetics of congenital erythropoietic porphyria. *Semin Liver Dis* 1998; **18**: 77–84.
- 118 Ged C, Moreau-Gaudry F, Richard E, Robert-Richard E, de Verneuil H. Congenital erythropoietic porphyria: mutation update and correlations between genotype and phenotype. *Cell Mol Biol (Noisy-le-grand)* 2009; **55**: 53–60.
- 119 Phillips JD, Steensma DP, Pulsipher MA, Spangrude GJ, Kushner JP. Congenital erythropoietic porphyria due to a mutation in GATA1: the first trans-acting mutation causative for a human porphyria. *Blood* 2007; **109**: 2618–21.
- 120 Kontos AP, Ozog D, Bichakjian C, Lim HW. Congenital erythropoietic porphyria associated with myelodysplasia presenting in a 72-year-old man: report of a case and review of the literature. *Br J Dermatol* 2003; **48**: 160–64.
- 121 Harada FA, Shwayder TA, Desnick RJ, Lim HW. Treatment of severe congenital erythropoietic porphyria by bone marrow transplantation. *J Am Acad Dermatol* 2001; **45**: 279–82.
- 122 Shaw PH, Mancini AJ, McConnell JP, Brown D, Kletzel M. Treatment of congenital erythropoietic porphyria in children by allogeneic stem cell transplantation: a case report and review of the literature. *Bone Marrow Transplant* 2001; **27**: 101–05.
- 123 Fritsch C, Lang K, Bolsen K, Lehmann P, Ruzicka T. Congenital erythropoietic porphyria. *Skin Pharmacol Appl Skin Physiol* 1998; **11**: 347–57.
- 124 Robert-Richard E, Moreau-Gaudry F, Lalanne M, et al. Effective gene therapy of mice with congenital erythropoietic porphyria is facilitated by a survival advantage of corrected erythroid cells. *Am J Hum Genet* 2008; **82**: 113–24.
- 125 Elder GH, Roberts AG. Uroporphyrinogen decarboxylase. *J Bioenerg Biomembr* 1995; **27**: 207–14.
- 126 Hessels J, Voortman G, van der Wagen A, van der Elzen C, Scheffer H, Zuijderhoudt FM. Homozygous acute intermittent porphyria in a 7-year-old boy with massive excretions of porphyrins and porphyrin precursors. *J Inherit Metab Dis* 2004; **27**: 19–27.
- 127 Llewellyn DH, Smyth SJ, Elder GH, Hutchesson AC, Rattenbury JM, Smith MF. Homozygous acute intermittent porphyria: compound heterozygosity for adjacent base transitions in the same codon of the porphobilinogen deaminase gene. *Hum Genet* 1992; **89**: 97–98.
- 128 Frank J, McGrath J, Lam H, Graham RM, Hawk JL, Christiano AM. Homozygous variegate porphyria: identification of mutations on both alleles of the protoporphyrinogen oxidase gene in a severely affected proband. *J Invest Dermatol* 1998; **110**: 452–55.
- 129 Roberts AG, Puy H, Dailey TA, et al. Molecular characterization of homozygous variegate porphyria. *Hum Mol Genet* 1998; **7**: 1921–25.
- 130 Kauppinen R, Timonen K, von und zu Fraunberg M, et al. Homozygous variegate porphyria: 20 y follow-up and characterization of molecular defect. *J Invest Dermatol* 2001; **116**: 610–13.
- 131 Martasek P, Nordmann Y, Grandchamp B. Homozygous hereditary coproporphyria caused by an arginine to tryptophane substitution in coproporphyrinogen oxidase and common intragenic polymorphisms. *Hum Mol Genet* 1994; **3**: 477–80.
- 132 Schmitt C, Gouya L, Malonova E, et al. Mutations in human CPO gene predict clinical expression of either hepatic hereditary coproporphyria or erythropoietic harderoporphyria. *Hum Mol Genet* 2005; **14**: 3089–98.
- 133 Lamoril J, Puy H, Gouya L, et al. Neonatal hemolytic anemia due to inherited harderoporphyria: clinical characteristics and molecular basis. *Blood* 1998; **91**: 1453–57.
- 134 Jaffe EK, Stith L. ALAD porphyria is a conformational disease. *Am J Hum Genet* 2007; **80**: 329–37.
- 135 Gross U, Sassa S, Jacob K, et al. 5-Aminolevulinic acid dehydratase deficiency porphyria: a twenty-year clinical and biochemical follow-up. *Clin Chem* 1998; **44**: 1892–96.
- 136 Doss MO, Stauch T, Gross U, et al. The third case of Doss porphyria (delta-amino-levulinic acid dehydratase deficiency) in Germany. *J Inherit Metab Dis* 2004; **27**: 529–36.
- 137 Sassa S, Kappas A. Hereditary tyrosinemia and the heme biosynthetic pathway. Profound inhibition of delta-amino-levulinic acid dehydratase activity by succinylacetone. *J Clin Invest* 1983; **71**: 625–34.
- 138 Zuazo E, Garaizar C, Labayru M, Prats JM. Neurological crisis in type 1 hereditary tyrosinemia. *Neurologia* 1994; **9**: 296–99.
- 139 Thunell S, Henrichson A, Floderus Y, et al. Liver transplantation in a boy with acute porphyria due to aminolaevulinic acid dehydratase deficiency. *Eur J Clin Chem Clin Biochem* 1992; **30**: 599–606.
- 140 Deybach JC, Badminton M, Puy H, et al. European porphyria initiative (EPI): a platform to develop a common approach to the management of porphyrias and to promote research in the field. *Physiol Res* 2006; **55** (suppl 2): 67–73.